

TACTICS OF RECONSTRUCTIVE AND PLASTIC SURGICAL OPERATIONS IN DIABETIC FOOT SYNDROME

Matmuratov Kuvondik Jumaniyazovich,
Sattarov Inayat Saparbaevich,
Atajonov Tulkinbek Shavkatovich,
Safarov Farkhod Abdukhalilovich,
Norzhigitov Sarvar Abdukayumovich

Abstract:

Inadequate surgical intervention technique selection in the construction of an appropriate foot is linked to high rates of reoperations and the prevalence of postoperative sequelae. The selection of the surgical technique based on the affected area is crucial for the formation of a weight-bearing foot. It is also important to maintain the integrity of the nutrient artery in a particular area of the foot, which is vital for feeding the foot's tissues. An adequate assessment of the peripheral arterial bed is crucial in this case.

The aim of this research focused to enhance the outcomes of treating wound defects in diabetic foot syndrome by employing a distinct method to foot surgery.

Keywords: diabetes mellitus, neurotrophic ulcers, reconstructive plastic surgery.

Introduction:

Incorrect choice of surgical technique in the formation of a suitable foot is associated with a high frequency of repeated operations and the prevalence of postoperative complications. The choice of surgical technique, depending on the area of the lesion, is crucial for the formation of a foot capable of carrying weight. It is also important to maintain the integrity of the nutrient artery in a specific area of the foot, which is vital for the nutrition of foot tissues. In this case, an adequate assessment of the condition of the peripheral arterial bed is crucial. The aim of this study was to improve the results of the treatment of wound defects in diabetic foot syndrome by applying a special method of foot surgery. Diabetes mellitus (DM) is one of the main health problems of the 21st century. The number of patients with diabetes has been steadily increasing over the past three decades, and this growth is likely to continue over the next few decades: from about 463 million patients aged 18 to 99 in 2019 to about 700 million people in the same age group in 2045 worldwide [2, 11].

Modern aspects of the development of blighty health care include a number of measures aimed at improving the treatment outcomes of patients with DM and DFS, who need constant monitoring due to the introduction of modern principles of intensive care, surgical tactics and improvement of reconstructive operations [1, 4, 6].

One of the most severe disabling complications of diabetes mellitus is DFS, which manifests itself in the development of widespread purulent-necrotic processes in the lower extremities, which are observed in 35-60% of patients with DM [3, 8, 10].

Timely and adequate surgical treatment of patients with purulent-necrotic complications of DFS largely determines the course and outcome of the disease. Improvement of the results of surgical treatment of purulent-necrotic diseases of the feet in diabetes mellitus is currently associated with the maximum possible preservation of the опорной function of the affected limb. The most difficult patients are those with the neuroischemic form of DFS, whose condition is aggravated by both ischemia of the foot and progressive infection against the background of various concomitant diseases associated with deep neuropathy [5, 11].

When a purulent-necrotic process is present on the foot in the neuropathic form of DFS, the patient needs to undergo radical surgical treatment, if it is feasible, along with simultaneous closure (plastic surgery) of the surgical wound. This is crucial for patients who have lower extremity gangrene [1, 7, 12].

Treatment for lower extremity gangrene in the context of diabetes that results in a demarcation line consists of sophisticated conservative therapy that includes necrectomy and phased procedures. Disarticulation of the finger is carried out with resection of the proximal portion of the corresponding metatarsal bone if the course of diabetic gangrene is quite favorable, which occurs after 7–10 days of conservative therapy and the emergence of a distinct line of demarcation [9].

The literature data analysis revealed that there is still much work to be done in order to improve the tactical aspects of DFS surgical treatment. Regrettably, there are currently no studies that describe the methodology for preoperative planning and postoperative monitoring in patients with adverse prognostic variables and in this severe category of patients.

Inadequate surgical intervention technique selection in the construction of an appropriate foot is linked to high rates of reoperations and the prevalence of postoperative sequelae. The selection of the surgical technique based on the affected area is crucial for the formation of a weight-bearing foot. It is also important to maintain the integrity of the nutrient artery in a particular area of the foot, which is vital for feeding the foot's tissues. An adequate assessment of the peripheral arterial bed is crucial in this case.

The aim of this research focused to enhance the outcomes of treating wound defects in diabetic foot syndrome by employing a distinct method to foot surgery.

The main part

In present-day surgery, the risk of developing postoperative complications in the early postoperative period persists despite the detailed development of methods for reconstructive plastic surgery of the foot against the backdrop of DFS. This forces us to search for new ways to perform this surgical intervention. This situation prompted a unique scientific investigation

to develop a reliable technique for performing it and preventing an adverse course of the postoperative period in patients who have undergone reconstructive plastic surgery and have purulent-necrotic lesions of the foot.

Following reconstructive plastic surgery, patients must go through a rehabilitation period that corrects the function of metabolic disorders and is necessary for them to resume their social lives. Reconstructive plastic surgery techniques vary depending on the amount of healthy tissue present. The goal is to maintain the foot's function as much as possible, optimize the biomechanics of the foot to stabilize it, make it suitable for orthopaedic prosthetics, and avoid complications like postoperative trophic ulcers. Reconstructive plastic surgery kinds and techniques vary in surgical practice depending on how and when each of the above stages will be executed.

Indications for reconstructive plastic surgery and aspects of wound care following surgery, contingent on the foot's placement, are critical problems for the operating surgeon to solve in complex clinical scenarios. Patients in this category may see an increase in quality of life if their problems are promptly resolved and a new, distinct surgical intervention technique is developed, contingent upon the location of the foot wound defect.

This study analyzed the results of surgical treatment of 53 patients who received inpatient treatment in the department of purulent surgery of the multidisciplinary clinic of the Tashkent Medical Academy in 2021-2022, for whom reconstructive plastic surgery on the foot was performed using improved technology (depending on the location of the wound defect and the affected part feet).

Table 1. The nature of damage to the peripheral arteries of the lower extremities depending on the form of DFS, abs. (%)

Stricken arterial segment	Form of DFS		Total
	neuroischemic	neuropathic	
Femoropopliteal	1 (7,1)	4 (66,6)	5 (25,0)
Popliteal-tibio-peroneal	3 (21,4)	1 (16,7)	4 (20,0)
Arteries of the leg	8 (57,1)	-	8 (40,0)
Femoropopliteal and crural arteries	2 (14,2)	1 (16,7)	3 (15,0)
Total	14 (100)	6 (15,4)	20 (37,7)

Just before being admitted to the hospital, each patient received a comprehensive evaluation that included a detailed assessment of the peripheral arterial bed's state in order to guarantee an appropriate selection of surgical treatment strategies. Non-invasive research techniques, such as multispiral computed angiography of the lower extremity arteries and duplex evaluation, were employed for this goal. Furthermore, peripheral artery abnormalities of various degrees were present in 20 patients (37.7%). A thorough investigation revealed that,

of the 39 patients, only 6 (15.4%) had neuropathic form, while all 14 patients had lower extremity arterial injury (Table 2).

When an obvious segmental occlusion-stenotic process of the arteries of the lower extremities was detected in a patient, the task of endovascular revascularization was first set. For this purpose, balloon angioplasty was used, which was performed in 6 (42.8%) of 14 patients.

Depending on the location and kind of lesion, different surgical procedures were carried out in patients with wound defects or purulent-necrotic processes on the foot. Of them, 45 (85%) of the 53 patients had a phlegmon opening and necrectomy, which took first position. Furthermore, sharp foot amputations and amputations of fingers were carried out. Between the frequency of execution and the data obtained, we could not find any significant differences (Table 2).

Table 2. The nature of the primary surgical interventions performed on patients depending on the form of DFS, abs. (%)

Operation	Form of DFS		Total
	neuroischemic	neuropathic	
Finger amputation	2 (14,3)	3 (7,7)	5 (9,4)
Opening of phlegmon, necrectomy	11 (78,6)	34 (87,2)	45 (85,0)
Sharp's foot amputation	1 (7,1)	2 (5,1)	3 (5,6)
Total	14 (26,4)	39 (73,6)	53 (100)

Autodermoplasty (split skin graft) was performed in 19 patients, resection or removal of the affected bone + myoplasty – in 27, skin-sural plastic surgery – in 7. When performing surgical intervention, changes in biomechanics or its correction, the condition of local tissues and changes in the structure of bone tissue were taken into account feet (Fig. 1.).

A review of the collected data revealed that over half of the procedures (66.0%) were done on the midfoot. Only 13.2% of reconstructive procedures were done in the posterior heel region. In 20.8% of instances, surgical treatments were carried out for a wound defect or purulent-necrotic lesion of the distal region with injury to the metatarsal bones.

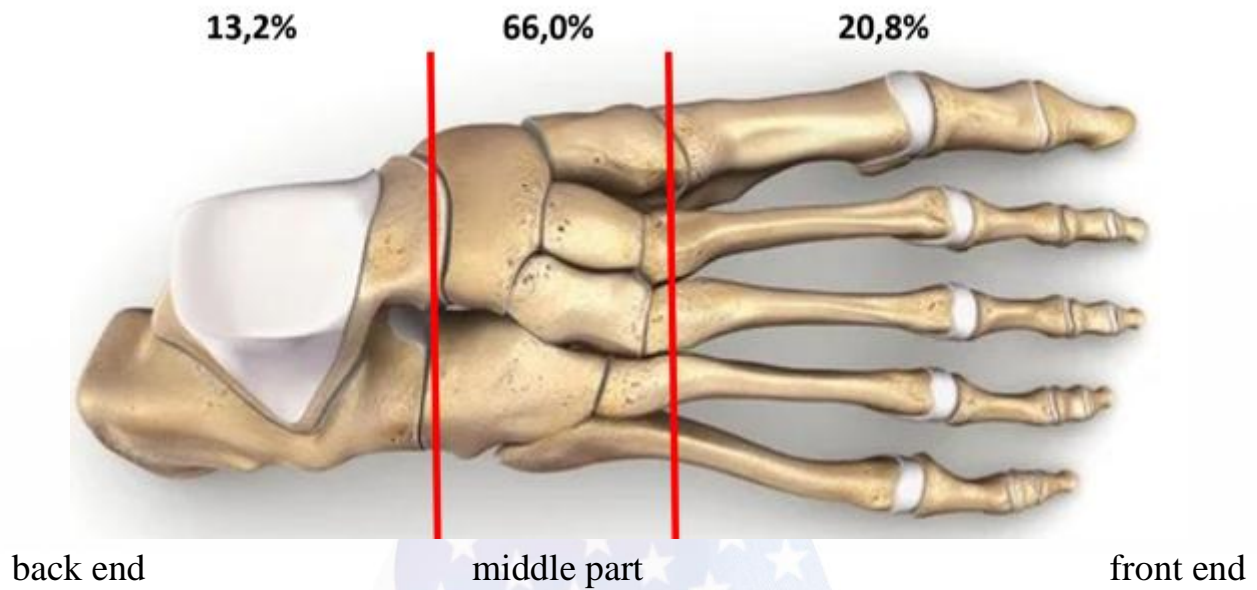


Fig. 1. Number of operations performed on parts of the foot.

Reconstructive plastic surgery on the foot was strictly divided based on the areas of the foot where the wound defect was found, following the revised method. In addition, autodermplasty accounted for the majority of these procedures in the middle 14.8% and the forefoot 36.8%. Diabetes-related osteoarthropathy frequently affects the midfoot because of the numerous bones and joints in this area of the foot as a result of altered foot biomechanics. The bulk of the patients, or 35 (66.0%) that we saw, had midfoot involvement. In the midfoot, combined reconstructive and plastic surgeries were performed, but in most cases it was necessary to perform myoplasty with resection or removal of the affected bone (85.2%) (Fig. 2).

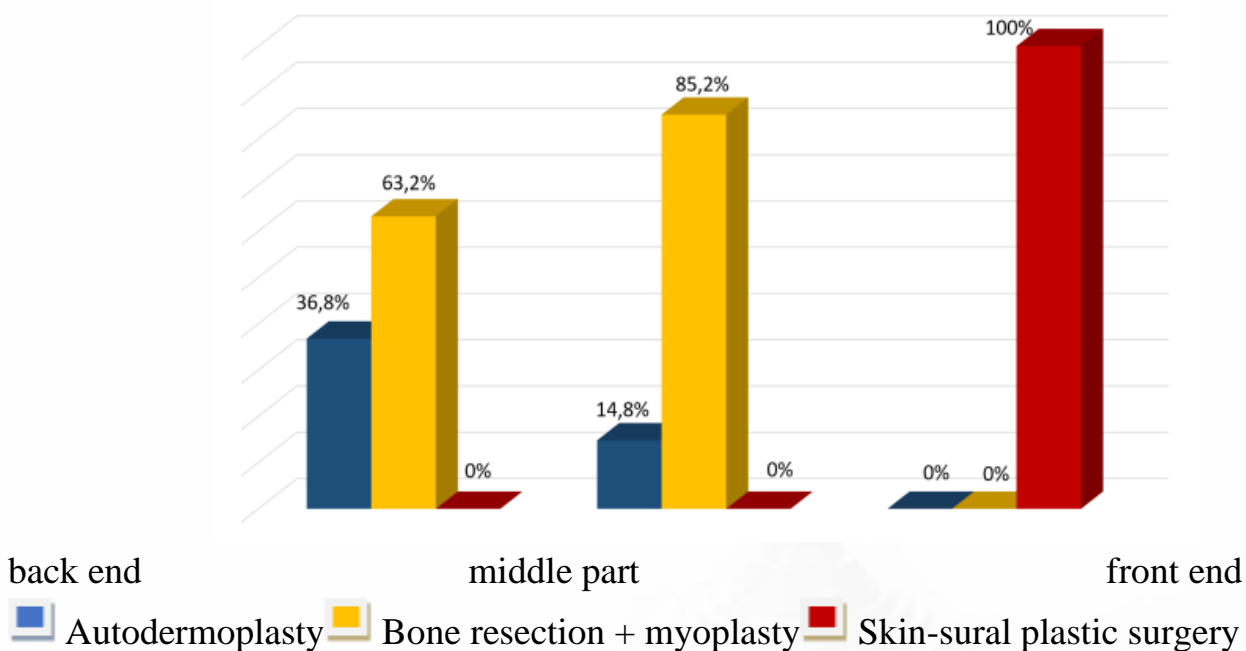


Fig. 2. Surgical interventions performed on parts of the foot.

Conclusion

In practical surgery, damage or localization of a wound defect in the heel region (back of the foot) has always presented particular difficulties for treatment. Firstly, this area does not have its own nutrient artery, secondly, the skin and subcutaneous tissue here have significant thickness, and thirdly, the back of the foot is the main area that coordinates the supporting function of the lower extremities.

Therefore, when performing surgical treatment of the foot in patients with a purulent-necrotic wound against the background of DFS, local soft tissue should be preserved as much as possible for secondary closure of the wound defect, especially in the heel area, since this area is most prone to secondary neurotrophic ulcers. Taking into account these parameters, we chose a different surgical treatment strategy aimed at reducing postoperative complications and creating a weight-bearing foot in terms of correcting altered biomechanics.

Table 3. Immediate results of treatment in patients depending on the form of DFS, abs. (%)

Treatment result	Form of DFS		Number of patients abs. (%)
	neuroischemic	neuropathic	
Smooth postoperative course	12 (85,8)	36 (92,3)	48 (90,6)
Postoperative wound suppuration	1 (7,1)	3 (7,7)	4 (7,5)
Neurotrophic ulcer formation	1 (7,1)	-	1 (1,9)
Total	14 (26,4)	39 (73,6)	53 (100)

Table 3 shows that 48 (90.6%) patients had a smooth postoperative course of primary wound healing. Positive outcomes were seen more frequently in the neuropathic form of DFS (92.3%). Four patients (7.5%) experienced wound suppuration during the postoperative period; in all of these cases, the infectious process was halted with the assistance of a sufficient regimen of treatment measures. Only one patient experienced a neurotrophic foot ulcer in the vicinity of the surgical site after being released from the hospital. We believe that the patient's extra body weight is related to this problem. Orthopedic shoes were advised for the patient in order to straighten the foot and avoid further issues.

In our line of work, we frequently encounter foot ischemia brought on by DFS, which frequently necessitates multiple surgical procedures. Thus, the number of patients in our clinic experiencing purulent complications has dropped to 9.4% over the last three years thanks to the developed differentiated method of reconstructive plastic surgery based on the affected part of the foot, and postoperative mortality was not noted at the time of data analysis.

Depending on the impaired anatomical structure of the main group's foot, a well-chosen approach and distinct method of reconstructive cosmetic surgery of the foot proved to be

highly effective in treating patients with wound abnormalities. Of the patients in the main group, 48 (90.6%) had their surgical wound heal completely. Inflammation and superficial suppuration in the wound region occurred in 4 (7.5%) of the patients during the recovery phase. Only local conservative therapy can be used to successfully treat profound suppuration, as long as it is localized, confined, and the surrounding tissues have enough blood supply.

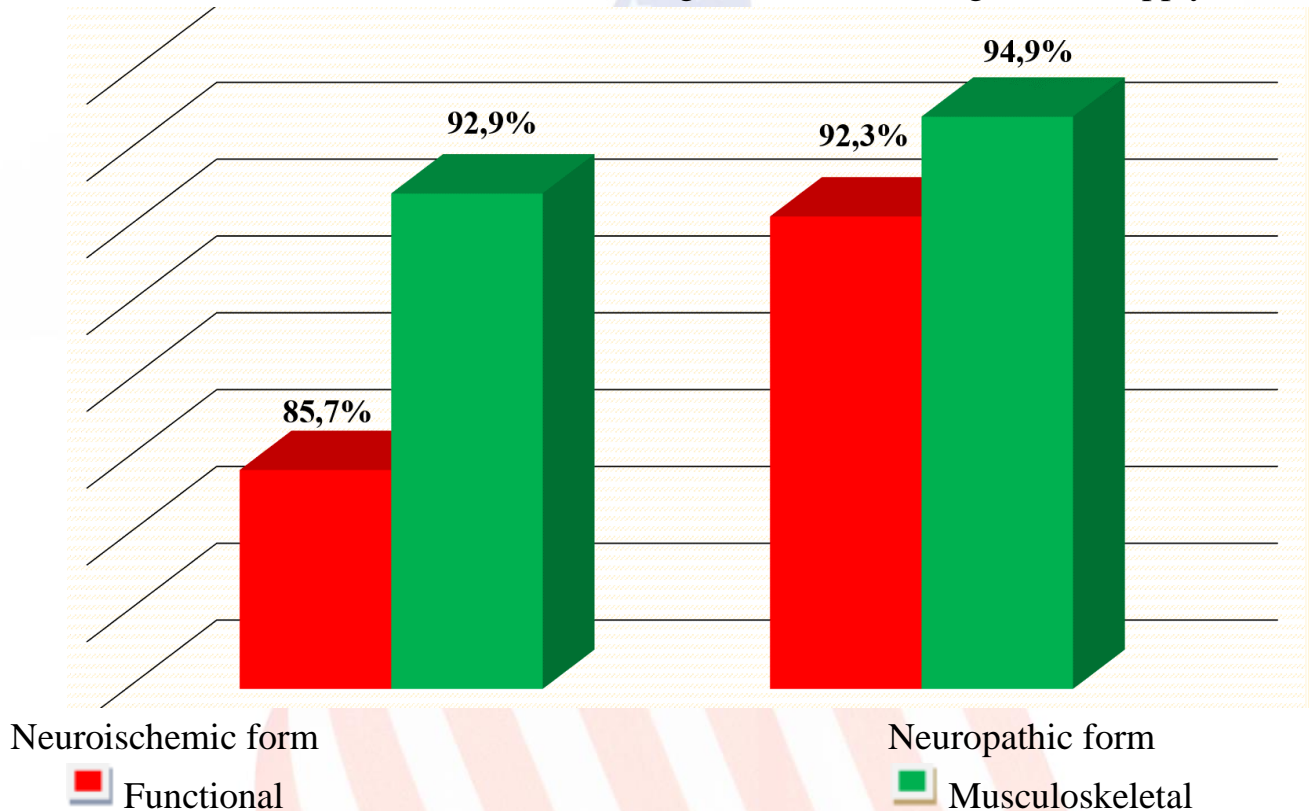


Fig. 3. Preservation of the foot in patients depending on the form of DFS.

With the help of an adequately selected differentiated surgical method in patients of the main group, we were able to increase the frequency of foot preservation. The functional safety of the foot in the neuroischemic form of DFS was 85.7%, and in the neuropathic form – 92.3%. Musculoskeletal safety in the neuropathic form of DFS was 2.0% higher than in the neuroischemic form (Fig. 3).

As a result, our method for carrying out reconstructive plastic surgery has improved. The location of the wound defect or purulent-necrotic focus on the foot is closely considered in this instance. Patients who suffered from a severe purulent process on their foot, also known as wet gangrene, were treated in two stages: in the first, the pathological focus was surgically cleaned, preserving as much of the surrounding questionable tissues as possible; in the second stage, reconstructive plastic surgery was planned, taking into account the local tissues and the location of the wound defect in a particular part of the foot. Each person's time was allocated for the second phase, which took an average of seven to ten days. We attempted to perform revascularization (balloon angioplasty) of the lower limbs first in cases of serious ischemia. This was followed by purulent-necrotic focus sanitation and reconstructive surgery.

Performing reconstructive plastic surgeries of the foot using a differentiated approach, taking into account the affected part, will allow maintaining an adequate weight-bearing foot with a minimal incidence of postoperative complications.

Conclusion:

1. The initial results (up to 3 months) in the comparison group (n=62) demonstrated that primary healing of the postoperative wounds occurs in 70.9% of cases ($p>0.05$) when patients with DBS undergo reconstructive plastic surgery using the standard method. 8.1% ($p>0.05$) of patients experienced purulent problems throughout the postoperative period. In 21.0% of patients ($p>0.05$), neurotrophic ulcers were seen to develop on the surgical foot soon after. Neurotrophic alterations were seen in 84.6 and 15.4% of cases with DFS in the neuropathic form, respectively, which is more common than the neuroischemic type.
2. Modifications to the foot's biomechanics and supporting point brought on by bone loss are the primary factor in the etiopathogenesis of neurotrophic ulcers against the background of DFS. Patients with purulent-necrotic foot lesions resulting from DFS should avoid potential complications after surgery by utilizing the best reconstructive surgical techniques in a timely manner.
3. Patients in the main group (n=53) who underwent differentiated reconstructive plastic surgery based on the location of their foot deformity experienced primary healing in 90.6% of instances ($p>0.05$), a considerably higher percentage than patients in the group comparison (70.9%). Neurotrophic ulcers were rare in this patient group throughout the postoperative phase, occurring in 1.9% of cases compared to 21.0% in the comparator group ($p>0.05$).

References

1. Алиева А.В., Акбаров З.С. Мембранные липиды и некоторые аспекты реализации эффекта инсулина на транспорт глюкозы при сахарном диабете // Мед. журн. Узбекистана. – 2017. – №5. – С. 95-98.
2. Бабаджанов Б.Д., Матмуротов К.Ж., Саттаров И.С., Атажанов Т.Ш. Эффективность анатомических резекций костей голени при диабетической гангрене нижних конечностей // Мед. журн. Узбекистана. – 2018. – №6. – С. 38-42.
3. Бабаджанов Б.Д., Матмуротов К.Ж., Саттаров И.С., Атаджанов Т.Ш., Сайтов Д.Н. Реконструктивные операции на стопе после баллонной ангиопластики артерий нижних конечностей на фоне синдрома диабетической стопы
4. Матмуротов К.Ж., Саттаров И.С., Қўчқоров А.А., Рузметов Н.А. Влияние микобактериальных ассоциаций на кратность повторных операций при диабетической гангрене нижних конечностей. «Вестник» ТМА, №6, 2021. Стр.106-111.

5. Матмуротов К. Ж., Саттаров И.С., Атажанов Т.Ш., Саитов Д.Н. Характер и частота поражения артериальных бассейнов при синдроме диабетической стопы. «Вестник» ТМА, №1, 2022. Стр.128-131.
6. Fauzi A.A., Chung T.Y., Latif L.A. Risk factors of diabetic foot Charcot arthropathy: a case-control study at a Malaysian tertiary care centre // Singapore Med. J. – 2016. – Vol. 57, №4. – P. 198-203.
7. Morbi A.H., Shearman C.P. Topical Negative Pressure Therapy for Diabetic Foot Ulcers: Where Is the Evidence // Int. J. Low Extrem. Wounds. – 2016. – Vol. 15, №1. – P. 96.
8. K.J.Matmurotov, S.S.Atafov, I.S.Sattarov, J.H.Otajonov. T.Sh.Atajanov. Bone resection features in leg amputation in patients with gangrene of lower extremities on the background of diabetes mellitus. American Journal of Medicine and Medical Sciences 2019, 9(7): 249-254
9. Peled E., Peter-Riesch B. The Diabetic Foot: The Never-Ending Challenge // Endocrinol. Dev. – 2016. – Vol. 31. – P. 108-134.
10. Santema T.K., Poyck P.P., Ubbink D.T. Systematic review and meta-analysis of skin substitutes in the treatment of diabetic foot ulcers: Highlights of a Cochrane Systematic review // Wound Repair Regen. – 2016. – Vol. 6.
11. Waycaster C.R., Gilligan A.M., Motley T.A. Cost-effectiveness of Becaplermin Gel on Diabetic Foot Ulcer Healing: Changes in Wound Surface Area // J. Amer. Podiatr. Med. Assoc. – 2016. – Vol. 6.
12. Zhang Z., Lv L. Effect of local insulin injection on wound vascularization in patients with diabetic foot ulcer // Exp. Ther. Med. – 2016. – Vol. 11, №2. – P. 397-402.